



## EDITORIAL

# Catheter ablation for acute management of electrical storm in ICD recipients: Is it prime time?



During the last few decades, we have experienced remarkable advances in the treatment and prognosis of ischemic and non-ischemic cardiomyopathy. In addition, the wider use of implantable cardioverter defibrillators (ICDs) has contributed to the improved survival of patients at increased risk of arrhythmic mortality. Because of the abovementioned facts, the number of patients with ICDs at advanced stages of heart failure, who are prone to develop electrical storm, has substantially increased. Although pharmaceutical therapy has been shown to improve prognosis, electrical storm has been shown to be a strong independent predictor of adverse long-term outcome despite the presence of an ICD.<sup>1–3</sup> Moreover, management of patients with electrical storm can be lengthy, often demanding hospitalization at intensive care units, which increases resource allocation and overall costs.

In this context, catheter ablation seems to be a promising therapy for patients with electrical storm, especially if they do not respond favorably to pharmaceutical treatment.<sup>4</sup> In the study by Paraskevaidis et al, patients underwent electrophysiologic study during the index hospitalization as soon as hemodynamic stability was achieved. In their study, index arrhythmia was abolished by catheter ablation in 75% of the studied patients. The results of this study are in accordance with other reports in the literature. In a recently published study from the Brigham and Women's Hospital at Boston, which evaluated data from 923 patients, 34% of ischemic cardiomyopathy patients and 27% of non-ischemic cardiomyopathy patients who underwent catheter ablation for ventricular arrhythmias had presented with electrical storm.<sup>5</sup> In this large cohort, there was a trend for more recurrence of electrical storm and more repeat procedures after index ablation in patients with non-ischemic cardiomyopathy than in those with ischemic cardiomyopathy. Given that catheter ablation of ventricular arrhythmias in Non-Ischemic Cardiomyopathy (NICM) can be complex, including the necessity for epicardial mapping and ablation, it is

obvious that an epicardial approach, although technically demanding, should be included in the armamentarium of those who treat patients with electrical storm. Hemodynamic instability, phrenic nerve palsy, proximity to major coronary arteries, and epicardial fat are some of the technical difficulties that need to be taken into consideration when performing epicardial ablation of ventricular arrhythmias. However, in patients with NICM, epicardial approach is often a prerequisite and thus has also been reported as a first-line therapy in patients with electrical storm (Figure 1).<sup>6</sup>

In conclusion, catheter ablation has a major role in the management of patients with electrical storm; the most important reasons for this are the following:

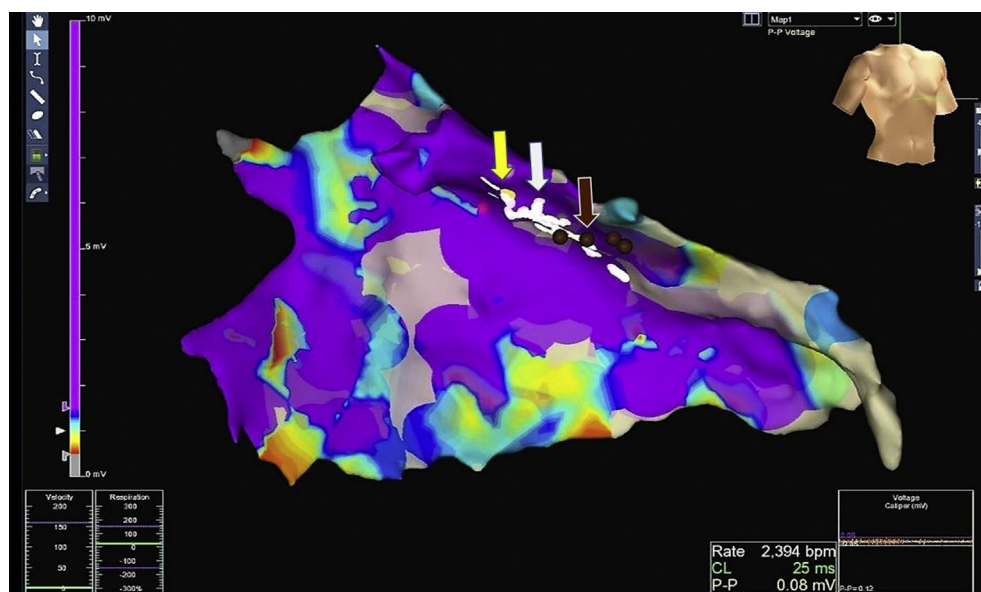
1. Catheter ablation is more effective than medical therapy, with a favorable effect on arrhythmia recurrence and prognosis.
2. Experience in catheter ablation of ventricular arrhythmias has been accumulated in most high-volume electrophysiology centers during the last decade.
3. Remarkable advances in the field of electrophysiology (fast anatomical mapping with multipolar catheters, respiratory gating through thoracic impedance measurement, use of electrode-tissue contact force catheters, and integration of pre-acquired CT/MRI data) have considerably improved the outcome and safety of complex ablation procedures.

However, hemodynamic stability before and during the procedure in patients who are considered candidates for the invasive management of electrical storm is possibly the most important clinical factor that determines appropriate management and short-term prognosis. Thus, efforts to achieve hemodynamic stability in all patients presenting with electrical storm is of profound importance and should include ventricular assist devices if needed.<sup>7</sup> It sounds plausible, but it is not. The main reason that restrains wider application of catheter ablation in the setting of electrical storm is neither the lack of experienced

Peer review under responsibility of Hellenic Society of Cardiology.

<http://dx.doi.org/10.1016/j.hjc.2017.04.001>

1109-9666/© 2017 Hellenic Society of Cardiology. Publishing services by Elsevier B.V. This is an open access article under the CC BY-NC-ND license (<http://creativecommons.org/licenses/by-nc-nd/4.0/>).



**Figure 1** Epicardial ablation of ventricular tachycardia originating from the anterolateral wall of the left ventricle in a patient with NICM who underwent unsuccessful endocardial ablation. The white dots show the area where RF energy was delivered and terminated the arrhythmia, the yellow dot indicates the proximal part of the left circumflex coronary artery, and the brown dots indicate the area where pacing caused phrenic nerve palsy. Notably, there are extensive areas of very low voltage (grey color) due to extensive ventricular fibrosis and accumulation of epicardial fat.

electrophysiologists nor the lack of appropriately equipped electrophysiology labs at the hospitals that mostly treat patients with electrical storm. The main reason is the lack of beds in intensive care units, when needed, and the lack of a well-organized team that could accommodate the efforts to optimize the hemodynamic condition of the patients, before, during, and after catheter ablation.

Thus, from the results of the study by Paraskevidis et al, which have been verified by other during the last few years, there are two important messages to consider when treating patients with electrical storm.

Catheter ablation should be considered as the treatment of preference for patients with electrical storm, especially for those that do not respond favorably to pharmaceutical treatment.

Second, electrophysiology centers that are likely to perform catheter ablation on patients with electrical storm should be prepared not only to provide advanced electrophysiological management during the ablation but also to undertake advanced hemodynamic support throughout the hospitalization period.

In conclusion, clinicians that treat patients who present with electrical storm should keep in mind the recommendation of the 2015 ESC Guidelines for the management of patients with ventricular arrhythmias: "Early referral of patients presenting with VT or VF storms to specialized ablation centres should be considered."<sup>8</sup> Those centers should be prepared to receive and treat those patients accordingly.

## References

1. Gatzoulis KA, Andrikopoulos GK, Apostolopoulos T, et al. Electrical storm is an independent predictor of adverse long-term outcome in the era of implantable defibrillator therapy. *Europace*. 2005;7:184–192.

2. Gatzoulis KA, Sideris SK, Kallikazaros IE, Stefanadis CI. Electrical storm: a new challenge in the age of implantable defibrillators. *Hellenic J Cardiol*. 2008 Mar-Apr;49(2):86–91.
3. Chiladakis JA, Spiroulis G, Koutsogiannis N, Zagli F, Alexopoulos D. Short-coupled variant of Torsade de Pointes as a cause of electrical storm and aborted sudden cardiac death: insights into mechanism and treatment. *Hellenic J Cardiol*. 2008 Sep-Oct;49(5):360–364.
4. Kolettis TM, Naka KK, Katsouras CS. Radiofrequency catheter ablation for electrical storm in a patient with dilated cardiomyopathy. *Hellenic J Cardiol*. 2005 Sep-Oct;46(5):366–369.
5. Kumar S, Fujii A, Kapur S, et al. Beyond the Storm: Comparison of Clinical Factors, Arrhythmogenic Substrate, and Catheter Ablation Outcomes in Structural Heart Disease Patients With versus Those Without a History of Ventricular Tachycardia Storm. *J Cardiovasc Electrophysiol*. 2017 Jan;28(1):56–67.
6. Faustino M, Agricola T, Xyheri B, Di Girolamo E, Leonzio L, Pizzi C. Electrical storm in dilated cardiomyopathy treated using epicardial radiofrequency ablation as a first line therapy. *Indian Heart J*. 2016 Sep;68(suppl 2):S218–S222.
7. Heinzmann D, Schibilsky D, Gramlich M, et al. Ablation of an electrical storm in a patient with giant cell myocarditis using continuous flow left ventricular assist device and percutaneous right ventricular assist device. *Int J Cardiol*. 2016 Apr 15;209:84–86.
8. Priori SG, Blomström-Lundqvist C, Mazzanti A, et al. 2015 ESC Guidelines for the management of patients with ventricular arrhythmias and the prevention of sudden cardiac death: The Task Force for the Management of Patients with Ventricular Arrhythmias and the Prevention of Sudden Cardiac Death of the European Society of Cardiology (ESC). Endorsed by: Association for European Paediatric and Congenital Cardiology (AEPC). *Eur Heart J*. 2015 Nov 1; 36(41):2793–2867.

---

George K. Andrikopoulos, MD , Director,  
*Electrophysiology & Pacing Department, First Cardiac  
Department, Henry Dunant Hospital Center, Athens,  
Greece*

*E-mail address:* [andrikop@hotmail.com](mailto:andrikop@hotmail.com)

29 January 2017  
Available online 19 April 2017