



CASE REPORT

# Subclinical cardiac involvement in thymomatous Myasthenia Gravis



Elias Giallafos, MD, PhD <sup>a,\*</sup>, Vasiliki Zouvelou, MD, PhD <sup>a</sup>,  
Sofia Maurogeni, MD, PhD <sup>b</sup>, Eleutherios Stamboulis, MD, PhD <sup>a</sup>

<sup>a</sup> 1st Department of Neurology, University of Athens, Greece

<sup>b</sup> Onassion Heart Center, Greece

Received 7 September 2014; accepted 8 June 2015

Available online 6 February 2017

## KEYWORDS

Myasthenia gravis;  
Cardiomyopathy;  
MRI;  
Holter

A 58-year-old man presented with a two-month history of eyelid ptosis and fatigue, emerging two months after thymectomy for an incidentally detected thymoma. Histological examination revealed type AB (spindle/oval-shaped neoplastic epithelial cells lacking nuclear atypia mixed with lymphocyte-rich foci) and IIA (macroscopic invasion into surrounding fatty tissue of mediastinal pleura) pathology according to the WHO and Masaoka classifications, respectively. Clinical examination revealed bilateral eyelid ptosis and weakness of the orbicularis oculi, upper and lower limbs and neck extensor muscles. The electrophysiological study showed disorder of the neuromuscular junction, and the serum acetylcholine receptor antibodies were positive with a titer of 46 nM (positive titer >0.6 nM). Pyridostigmine resulted in mild clinical improvement. A thorough cardiac evaluation was performed, including an

electrocardiogram, cardiac ultrasound, 24-hour ambulatory ECG (Holter) and cardiac magnetic resonance imaging (cMRI). Neither the ECG nor the echocardiogram showed any abnormalities related to MG; however, Holter monitoring showed a moderate number of premature ventricular contractions (PVCs) (>30 beats/hour) and one couplet of PVCs. Exercise stress testing was negative for coronary artery disease, although areas of enhancement in the interventricular septum and in the lateral wall of the LV (Fig. 1) were seen on cMRI T1 sequences, indicative of a fibrotic process. After the cardiac exams, the patient received 60 mg/d prednisolone for 6 months with clear clinical improvement, and subsequent cMRI and Holter results were normal.

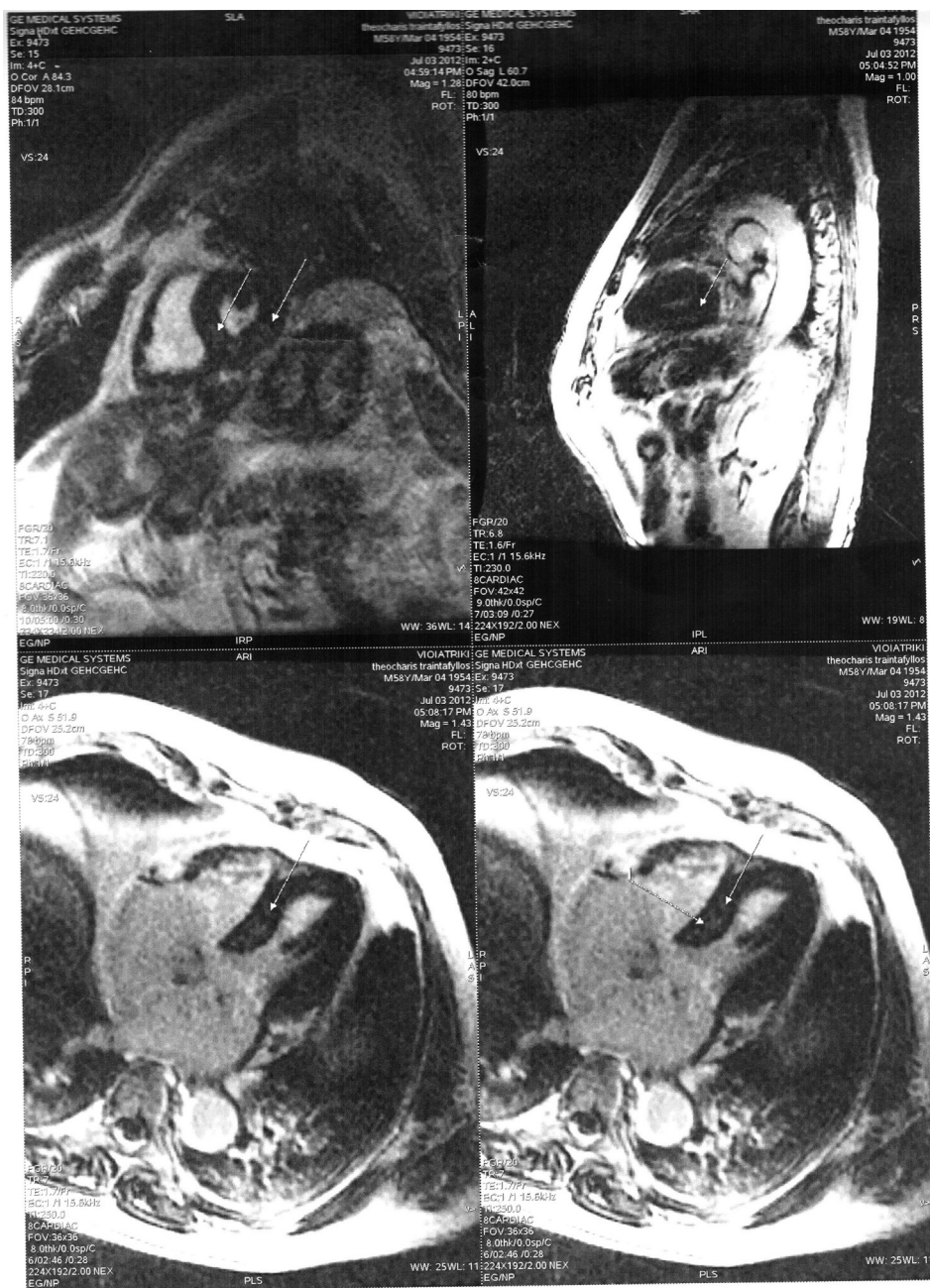
Myasthenia Gravis (MG) primarily affects skeletal muscles, but cardiac involvement has been reported in thymomatous MG.<sup>1</sup> Immunologic response against antigens such as titin and ryanodine<sup>2,3</sup> and inflammatory infiltrates have been suggested as possible causes of MG-induced cardiomyopathy. Autopsies in MG patients have revealed focal inflammation and necrosis throughout the myocardium, which seem to be correlated with the presence of thymoma.<sup>4</sup> In this case report, we provided further evidence of subclinical cardiac involvement in a thymomatous MG patient.

Although there are studies implying the presence of cardiomyopathy in thymomatous MG, this is, to the best of our knowledge, the first case in which cardiac abnormalities were detected by the use of MRI. Also notable is the significant number of PVCs on Holter monitoring, which was probably related to the fibrotic process and/or autonomic nervous system dysfunction that are found in MG.

\* Corresponding author. Elias Giallafos, MD, PhD. Tel.: +30 6944399924.

E-mail address: [gialaf@yahoo.com](mailto:gialaf@yahoo.com) (E. Giallafos).

Peer review under responsibility of Hellenic Cardiological Society.



**Figure 1** Gadolinium-enhanced MRI revealing hyperenhancing areas (arrows) in the myocardium of the lateral and interventricular septum probably due to fibrosis.

These electro-mechanical abnormalities are the result of multiple pathophysiological mechanisms that are implicated in the development of MG, involving CD4<sup>+</sup> T lymphocyte autoimmune mechanisms,  $\beta_1$  and  $\beta_2$  adrenergic receptor autoantibodies, and titin and ryanodine receptor antibodies.<sup>2,5</sup>

The first reviews of myasthenic heart disease emerged in the 1970s and included the association of thymoma with different forms of myocardial disease, such as giant cell myocarditis and Takotsubo cardiomyopathy.<sup>4,6</sup> Myocardial damage is usually detected long after the diagnosis of MG, but in our case, there was concurrent presentation of cardiac involvement and myasthenia.

Cardiac involvement in MG can be suspected when electrocardiographic and/or wall motion abnormalities on echocardiography are present. MRI provides additional information regarding possible inflammatory and/or fibrotic processes in the myocardium and allows the opportunity to perform MRI-guided myocardial biopsy in order to identify the cardiomyopathy process and promptly initiate management with immunosuppressive therapy.

### Conflict of interest

None.

## Funding

None.

- Elias Giallafos has received scholarships from:
  1. Onassion Foundation
  2. Hellenic Heart Society

## References

1. Suzuki S, Utsugisawa K, Yoshikawa H, et al. Autoimmune targets of heart and skeletal muscles in myasthenia gravis. *Arch Neurol*. 2009 Nov;66(11):1334–1338.
2. Mygland A, Tysnes OB, Matre R, Aarli JA, Ghilus NE. Anti-cardiac ryanodine receptors in thymoma-associated myasthenia gravis. *Autoimmunity*. 1994;17:327–331.
3. Aarli JA. Herzmyasthenie: myasthenia of the heart. *Arch Neurol*. 2009;66:1322–1323.
4. Gibson TC. The heart in Myasthenia Gravis. *Am Heart J*. 1975 Sep;90(3):389–396.
5. Xu BY, Pirskanen R, Lefvert AK. Antibodies against beta1 and beta2 adrenergic receptors in myasthenia gravis. *J Neuroimmunol*. 1998 Nov 2;91(1–2):82–88.
6. Bansal V, Kansal MM, Rowin J. Broken heart syndrome in myasthenia gravis. *Muscle Nerve*. 2011 Dec;44(6):990–993.